

MICRODENT BONE EXPANSION AND AND CONDENSATION

PRODUCT CATALOGUE

www.microdentsystem.com



CONTENTS

03

**Bone Expansion
and condensation**

06

Surgical kits

09

Surgical instruments

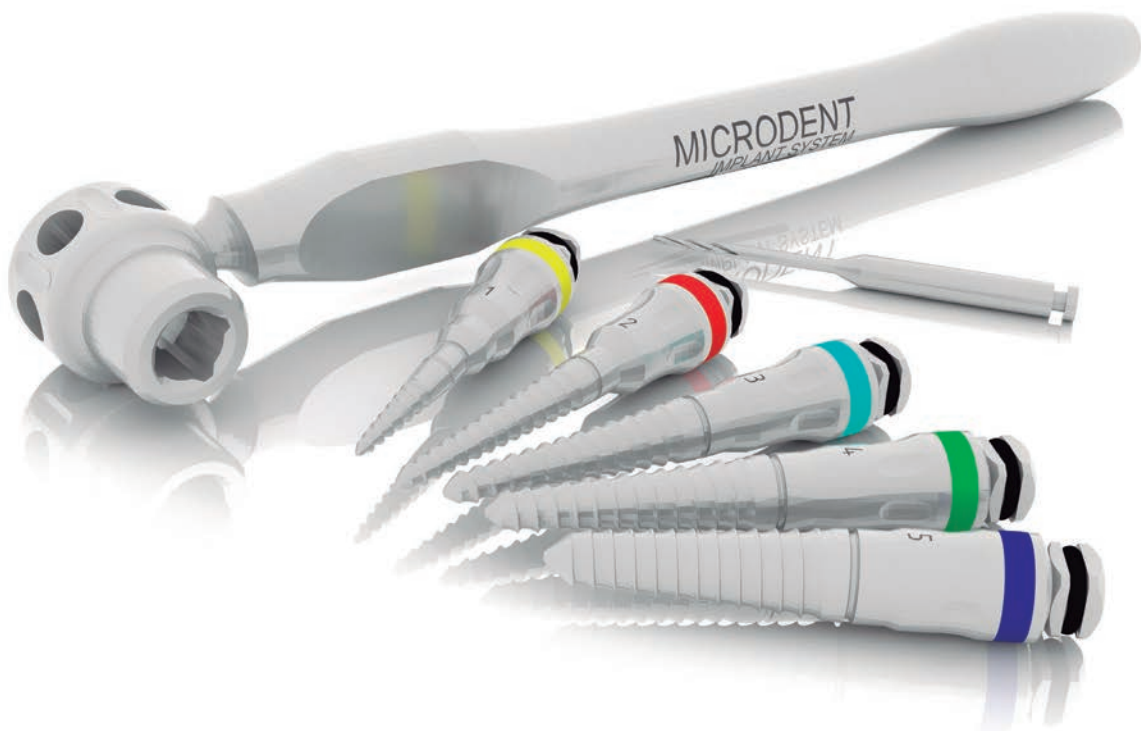
12

Clinical considerations

13

Clinical cases

MICRODENT BONE EXPANSION AND CONDENSATION



MICRODENT BONE EXPANSION AND CONDENSATION

MICRODENT BONE EXPANSION AND CONDENSATION SYSTEM

Bone expansion plays a vital role in implant dentistry today. Microdent bone expanders constitute a very important technological innovation for oral rehabilitation and have become a worldwide reference product and a must for any implantology professional, due to the fact that they reduce surgical trauma to a minimum and allow an effective measured and progressive control of the expansion in areas of limited width and density, increasing the thickness without bone loss.

During the procedure, perfect control of the implant insertion axis is achieved and it also replaces the use of most drills.

Their dual use, as bone condensers, facilitates the improvement of bone density and as a result a bone is obtained with the ideal quality for subsequent implant treatment, and the achievement of perfect osseointegration and implant success in the medium-long term.

In 1997, Microdent registered a worldwide patent for the first threaded expanders and condensers for atraumatic threaded bone expansion and condensation techniques.

Patent in Spain: 9602250

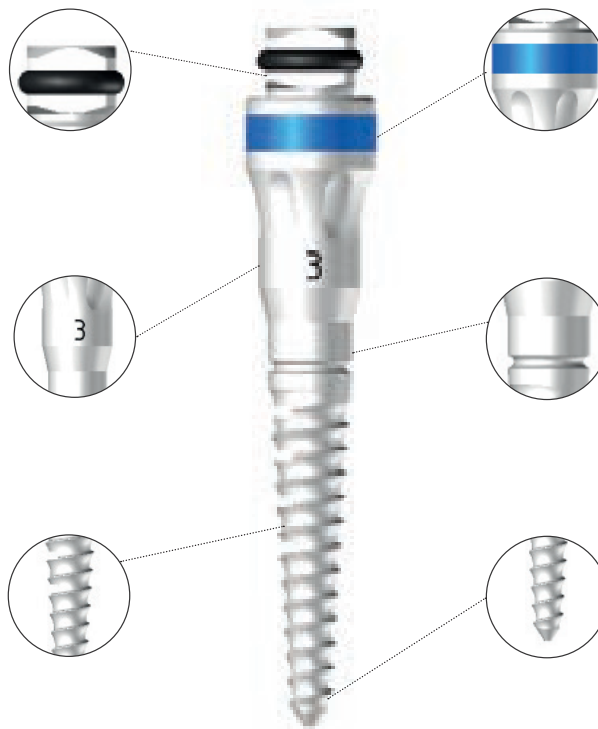US Patent: 6146138

Patent in Europe: 023801558

Square connection for contra-angle (LC44), manual extra oral (LLEO) and ratchet spanners (LD1).

Numeric code for easy identification as a complement to colour identification.

Depth marks from 8 to 16 mm for greater control of the drilled holes.



Colour code for quick identification (according to thickness from smallest to largest: yellow-red-blue-green-black).

Made of stainless steel resistant to prolonged use, to guarantee its functionality.

The thread pitch achieves a condensation effect that improves bone quality for immediate loading, whereas the bleeding produced favours osseointegration.

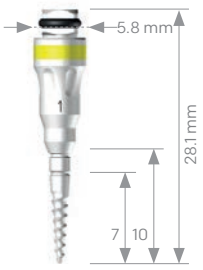
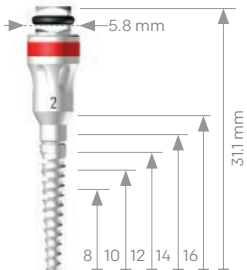
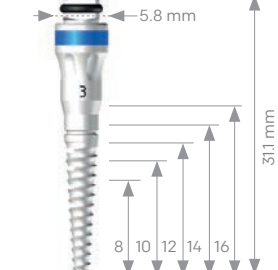
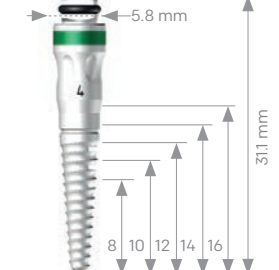
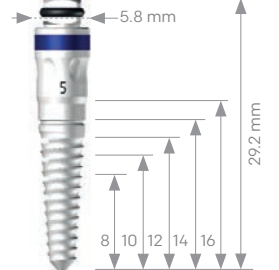


The use of Microdent expanders and condensers (universal for all implant systems) improves the success rates of placed implants.

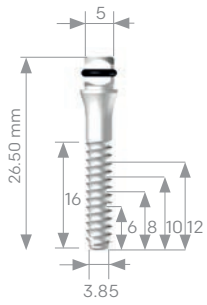
MICRODENT EXPANDERS AND CONDENSERS

Microdent expanders and condensers make it possible to rehabilitate complex areas, reversing the process of bone loss through the three-dimensional remodelling of the bone tissue architecture both qualitatively and quantitatively.

Technical characteristics of the product

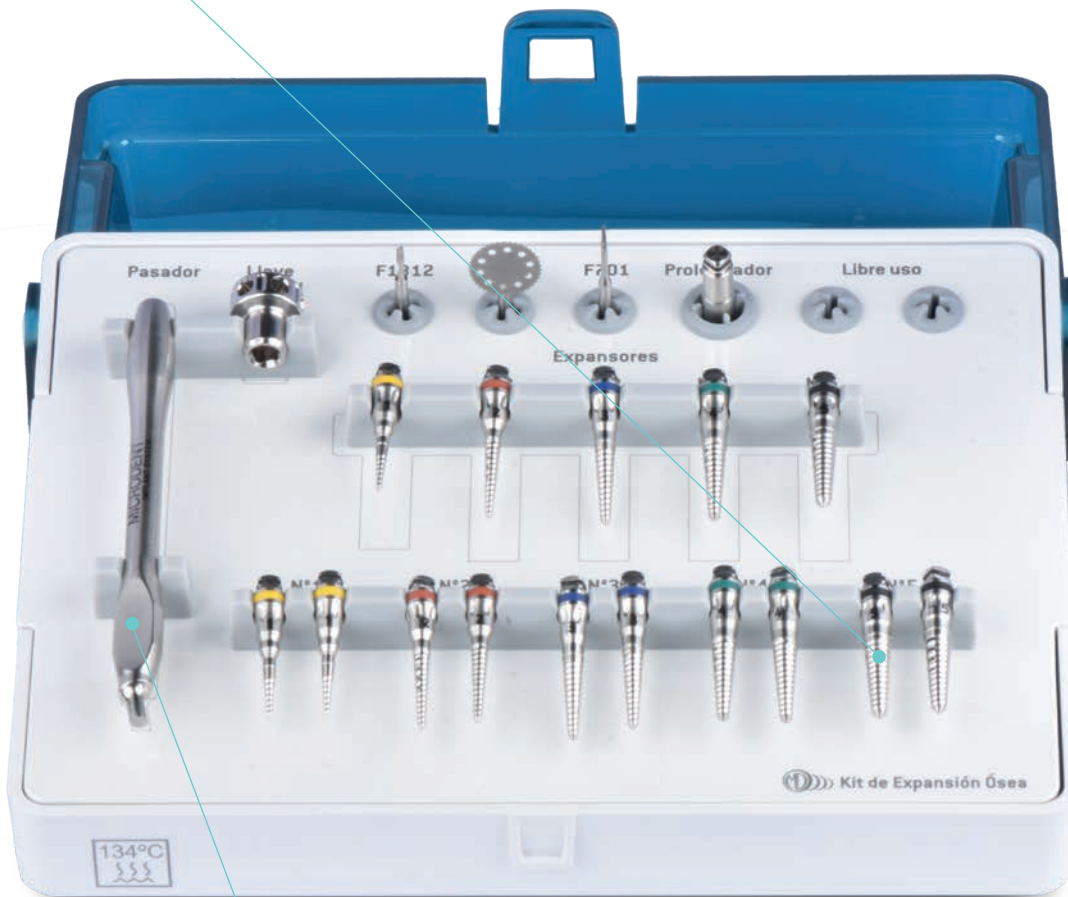No. 1 1025	No. 2 1830	No. 3 2938	No. 4 3345	No. 5 4452
				
Initiation expander Tip Ø 1.00 mm up to 2.30 mm Length 10 mm	Tip Ø 1.50 mm up to 3.00 mm 8mm = Ø 2.20 mm 10mm = Ø 2.40 mm 12mm = Ø 2.60 mm 14mm = Ø 2.80 mm	Tip Ø 1.90 mm up to 3.80 mm 8mm = Ø 2.75 mm 10mm = Ø 3.00 mm 12mm = Ø 3.25 mm 14mm = Ø 3.50 mm	Tip Ø 2.30 mm up to 4.50 mm 8mm = Ø 3.30 mm 10mm = Ø 3.60 mm 12mm = Ø 3.90 mm 14mm = Ø 4.20 mm	Tip Ø 3.00 mm up to 5.00 mm 8mm = Ø 3.90 mm 10mm = Ø 4.20 mm 12mm = Ø 4.50 mm 14mm = Ø 4.70 mm

In addition, the sinus lifter allows atraumatic sinus lifting, avoiding fracture of the bone plate.

Sinus lifter 3535

Straight Ø 3.50 mm For implants Ø 4.00 mm Ø 4.20 mm

SURGICAL KITS

3 sets of expanders to facilitate surgery with extensive corticotomies.



Spanner to maximise control of the expansion and properly manage the speed of the technique.

The Microdent Bone Expansion and Bone Condensation kits are equipped with all the necessary instruments for the correct application of each of these techniques. An intelligent and elegant design, developed to offer maximum comfort to the clinician.

ADVANCED EXPANSION KIT

The advanced expansion kit contains the ideal instruments for the bone expansion technique, including a triple set of each expander for better control of the technique process and in order to achieve better primary stability in the subsequent placement of the implant. This kit includes the following items:

KE03J

- Circular drill Ref. F101
- Pilot drill for expanders Ref. F1312
- Ridge opening drill Ref. 701
- Long extension Ref. ACL44
- Manual spanner Ref. 644
- Spanner pin Ref. 35
- Expander No.1 (3 units) Ref. 1025
- Expander No.2 (3 units) Ref. 1830
- Expander No.3 (3 units) Ref. 2938
- Expander No.4 (3 units) Ref. 3345
- Expander No.5 (3 units) Ref. 4452

Optional material (bottom tray) not included:

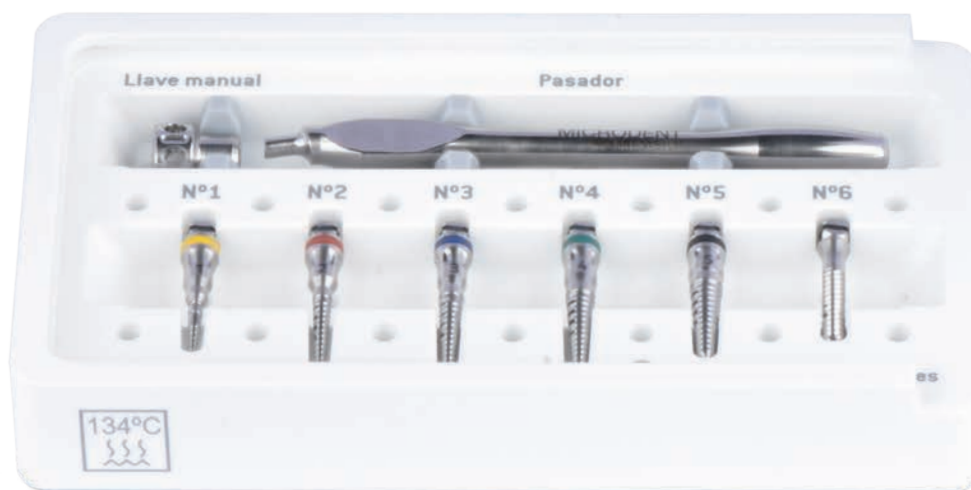
- Ratchet spanner Ref. LD1
- Extra oral spanner Ref. LLEO

BASIC EXPANSION KIT

The basic expansion and condensation kit contains the necessary instruments to achieve adequate condensation to improve bone quality and density. This kit includes the following items:


KBE

- Manual spanner Ref. 644
- Spanner pin Ref. 35
- Expander No.1 Ref. 1025
- Expander No.2 Ref. 1830
- Expander No.3 Ref. 2938
- Expander No.4 Ref. 3345
- Expander No.5 Ref. 4452
- Sinus lifter Ref. 3535



SURGICAL INSTRUMENTS

Drill for longitudinal opening of the ridge in the first clinical phase of the expansion process, used at high speed.



Manual spanner that provides sensitive control of the entire expansion or condensation process.

Instruments for the application of the protocols for the bone expansion and condensation techniques that now also offer a new treatment on the drills and permit a better reading and control of the depth, all of this with the final objective of conditioning an ideal bed in areas with complicated initial characteristics.

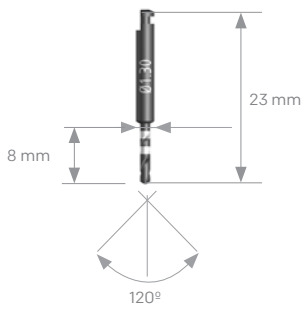
SURGICAL INSTRUMENTS

SURGICAL INSTRUMENTS

PILOT DRILL

Used to perforate the ridge and allow the introduction of expander no.1.

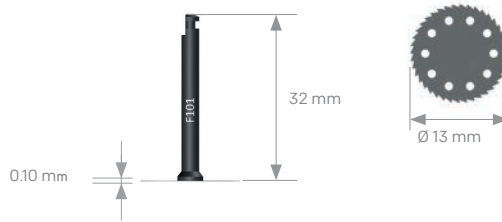F1312



CIRCULAR DRILL

Used for longitudinal opening of the ridge.

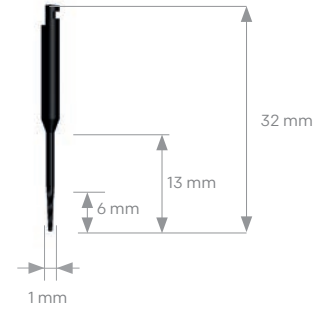
F101



DRILL 701

Used for longitudinal opening of the ridge, at high speeds.

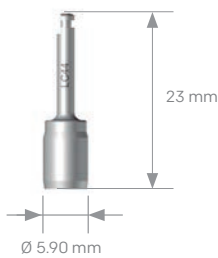
701



CONTRA-ANGLE SPANNER FOR METAL IMPLANT HOLDER AND EXPANDER

Used directly on the square connection of the expander.

LC44

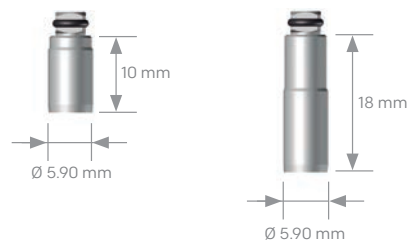


EXTENSION FOR EXPANDER

Used directly on the square connection of the expander.

ACC44

ACL44



PIN

For tightening of the manual spanner.

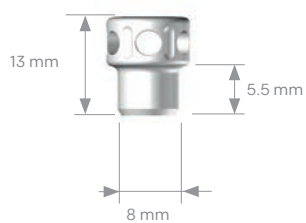
35



MANUAL SPANNER

Provides very sensitive control of expansion.


644



EXTRA ORAL SPANNER

Very practical spanner for expansion from the outside of the oral cavity.

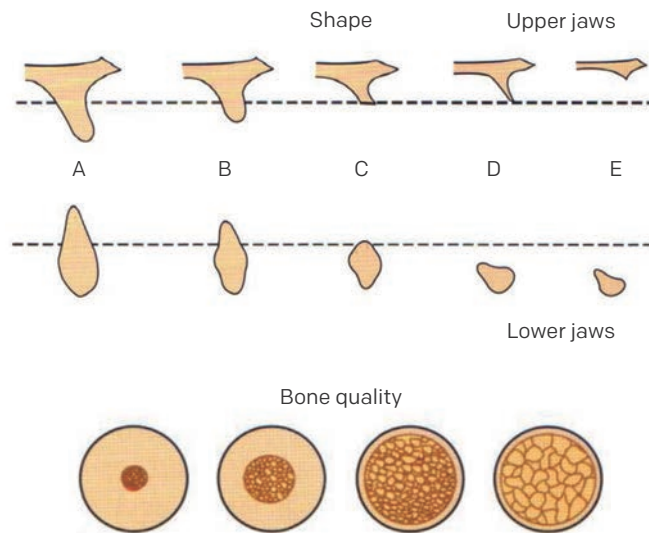
LLEO



CLINICAL CONSIDERATIONS

The residual shape of the jaws and their bone quality must be taken into account as clinical considerations to perform an excellent bone expansion and condensation procedure. Lekholm and Zarb - 1985-. (J. Lindhe, T. Karring, N.P. Lang, Clinical periodontology and implant dentistry. 5th Ed. Madrid: Ed Médica Panamericana; 2009.p. 53)

Bone type A	Bone type B	Bone type C	Bone type D	Bone type E
Bone with:	Bone with:	Characterised by:	Characterised by:	Characterised by:
<ul style="list-style-type: none"> - Width > 5mm - Height: 10-12 mm - Length > 5mm - Angulation > 30% 	<ul style="list-style-type: none"> - Width: 2.5 - 5 mm - Height: 10 - 12 mm - Length > 15mm - Angulation > 20% 	<ul style="list-style-type: none"> - Bone with unfavourable height and width as well as in length and angulation 	<ul style="list-style-type: none"> - Severe atrophy - Basal bone loss - Flat upper jaw - Pencil jaw 	<ul style="list-style-type: none"> - Extreme atrophy - Basal bone loss



SPECIFIC OBJECTIVES OF THE BONE EXPANSION AND CONDENSATION SYSTEM

Bone expansion	Lateral bone condensation	Sinus bone elevation
<ul style="list-style-type: none"> - Gain in bone width. Correct axial position and inclination of the implants. <ul style="list-style-type: none"> - Sufficient bone volume. - Its use is practically atraumatic. 	<ul style="list-style-type: none"> - Improved density. - Bone quality. - Increased lift surface area. Increased load resistance.	<ul style="list-style-type: none"> - Gain in bone width. Favourable intermaxillary relationship. <ul style="list-style-type: none"> - Standardization of intra oral relations.



A height of about 12 mm, a minimum vestibular, palatal and lingual cortical width of 2 mm and other considerations are necessary for predictable bone expansion over time.

CLINICAL CASES

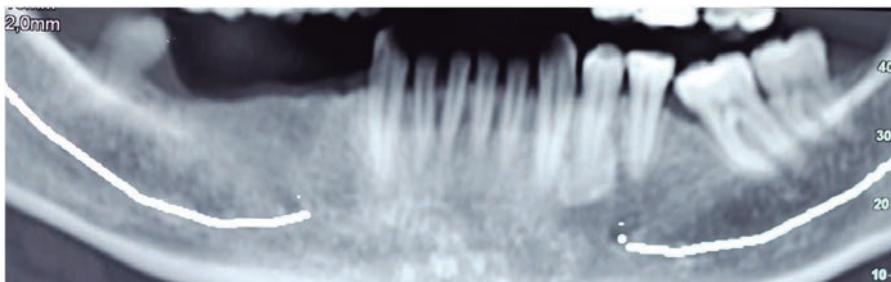
MICRODENT BONE EXPANSION AND CONDENSATION

CLINICAL CASE No.1

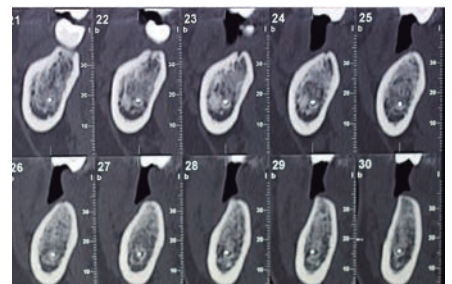
Clinical photos courtesy of **Dr. Holmes Ortega Mejía**

Expansion in non-extreme cases to recover cross-sectional dimension

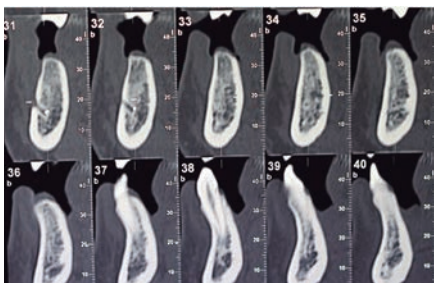
37 year old patient who comes to the clinic to recover teeth 4.4 - 4.5 - 4.6 - 4.7. It is decided to place 3 implants as the spaces have been reduced thanks to the mesialisation of 4.8.



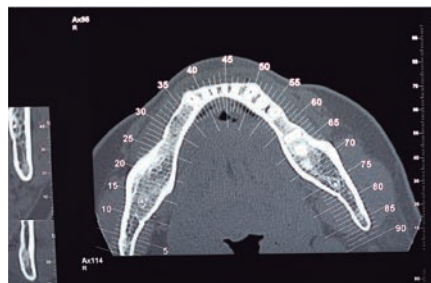
The expansion technique is a technique that seeks to increase the transverse diameter of the bone to be treated not only to be able to place implants, but also to increase the transverse volume and to be able to give a better emergence to the prosthesis.



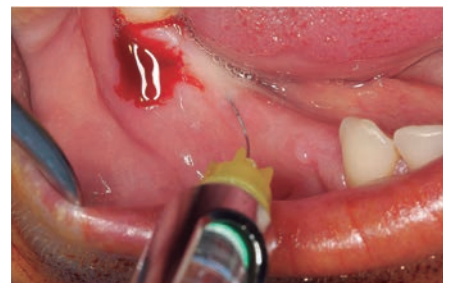In cases like this, placing implants should not be a difficulty, but if we want to obtain good emergence we will notice a lack of tissue in the vestibular region.



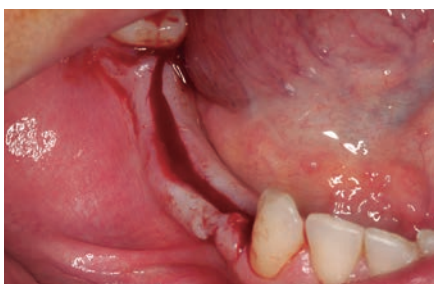Gaining a few millimetres transversely guarantees an adequate emergence for the prosthesis.



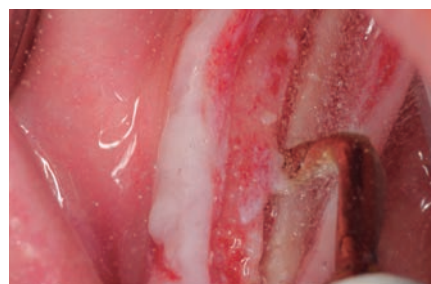At the third apical level, the loss of transversal space is not observed, but it is at the crestal level.



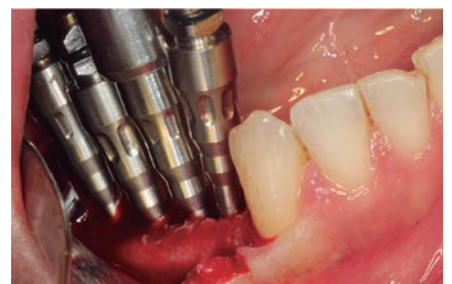Crestal anaesthesia is applied, transverse bone loss is observed clinically. Expansion will improve the emergence of the prosthesis.



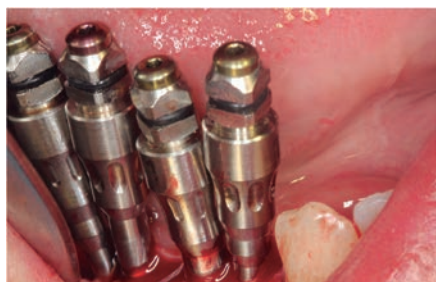Crestal-lingual incision to maintain a vestibular keratinized tissue.



Longitudinal piezoelectric corticotomy.



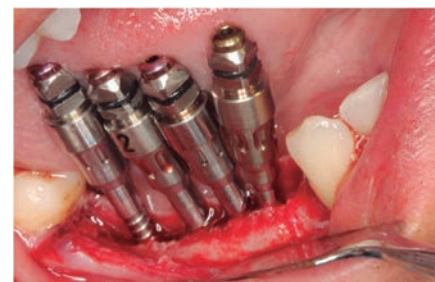We start the expansion protocol first with the yellow expanders, beginning with the centre of the corticotomy.



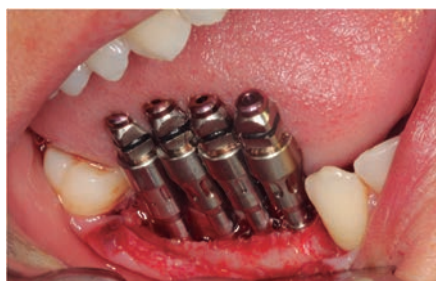Continuing with the protocol, we remove the yellow expander from the centre and replace it with a red one.



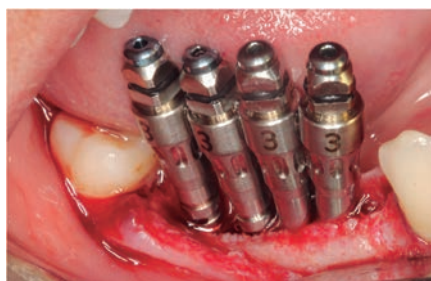We continue removing yellow expanders and replacing them with red ones, always from the centre towards the ends.



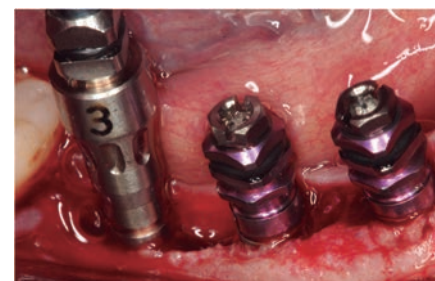Yellow to red expanders in the distal region.



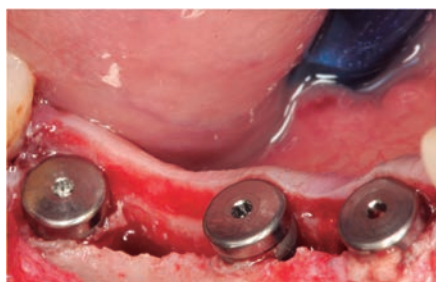Red expanders in the mesial region.



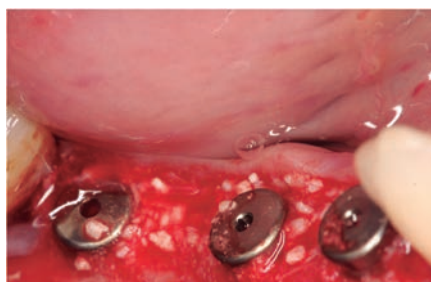
We continue with the same sequence and place expander no.3, which corresponds to the blue one.



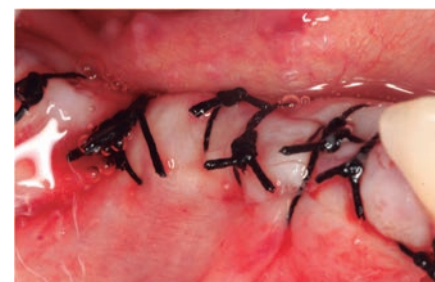We remove the blue expanders from the centre and place the MV4.20 x 12 mm expansion implant.



The same is done in the distal region, note the expansion obtained.



We fill with biomaterials (Apatos heterologous bone).



We suture with silk, thus avoiding injuries to the monofilament because it is in contact with the tongue.

CLINICAL CASE No.2

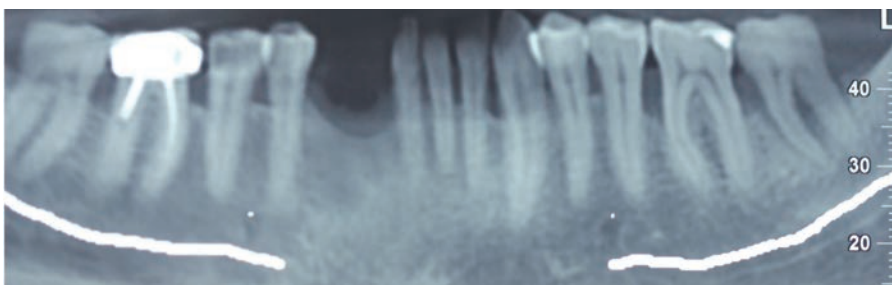
Clinical photos courtesy of **Dr. Holmes Ortega Mejía**

Expansion and delayed regeneration

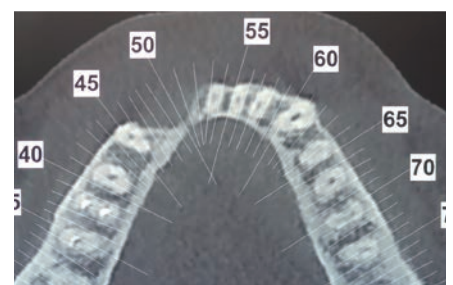
55-year-old patient who underwent extraction of teeth 4.2 with apical cysts and pockets larger than 9 mm, with recurrent abscesses.

Clinical examination revealed a loss of keratinised tissue and a transverse defect.

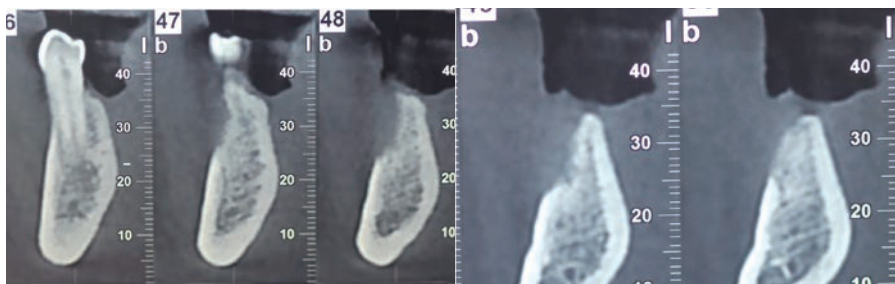
It is decided to do an FGG to obtain good tissue to protect the graft.



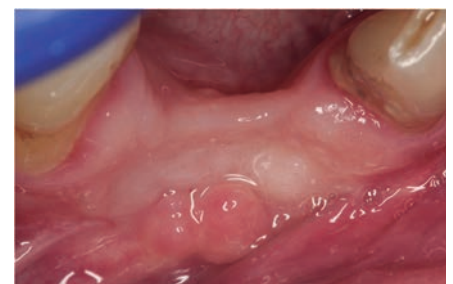The orthopantomography shows a slight vertical loss.



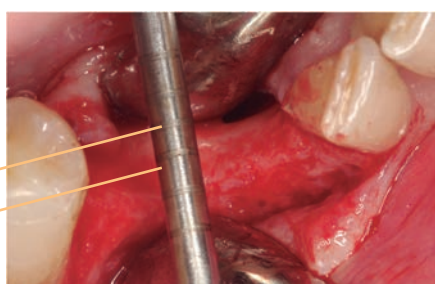
The tomographic study shows a transverse loss of bone tissue; loss of contour of the lower jaw is also observed.



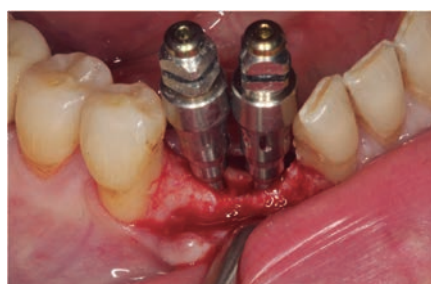In the axial cuts we could think about placing two implants which would be slightly submerged, losing 3 mm vertically, to obtain larger crowns; however, remember that the contour of the mandible in that sector has been lost and we would have implants that are too close together and with crowns that are too large.



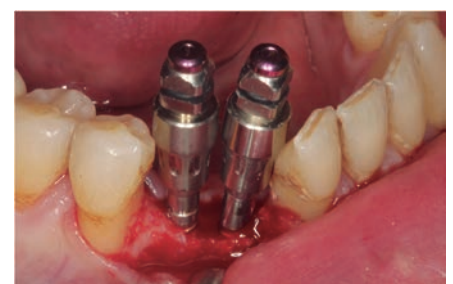An FGG is performed first to ensure the protection of the graft.



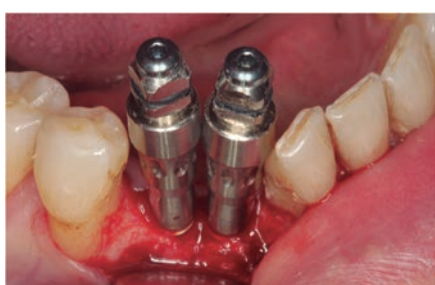It is possible to see the 2 mm of ridge and about 4 mm of defect.



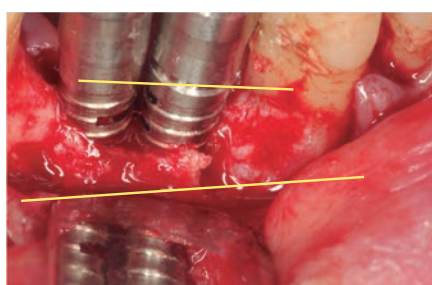
First the corticotomy is performed with piezoelectric surgery and then the expansion is started with the Microdent expanders.



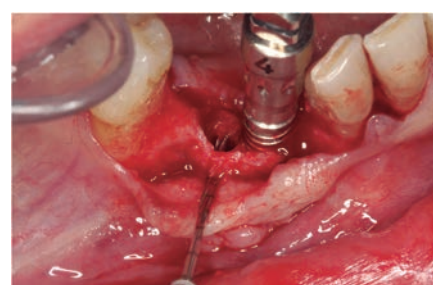
The yellow expanders (no.1) are removed and replaced by the red ones (no.2) deepening up to 14 mm.



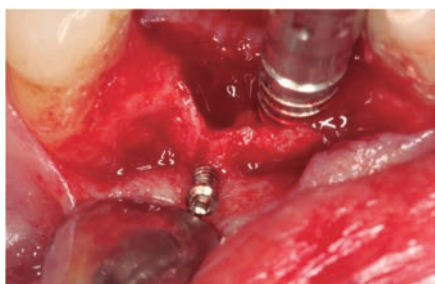
The protocol is continued changing the red expanders for the blue ones and deepening up to 14 mm.



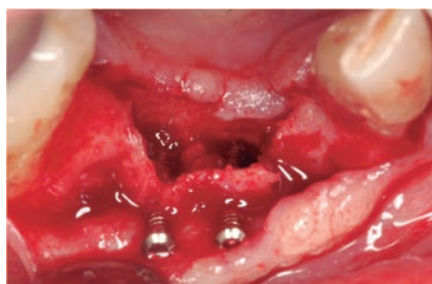A fracture is observed in the mesial region that does not involve the adjacent tooth.



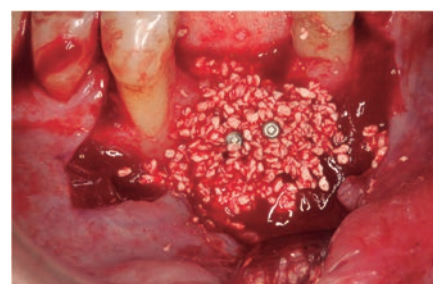One expander is removed and one osteosynthesis screw is placed.



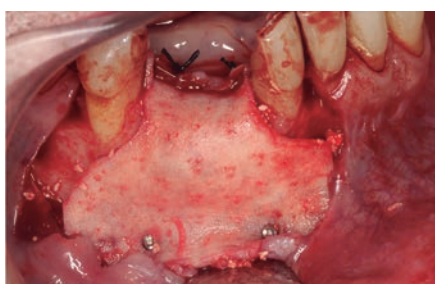Part of the osteosynthesis screw is left out for tent-pole regeneration.



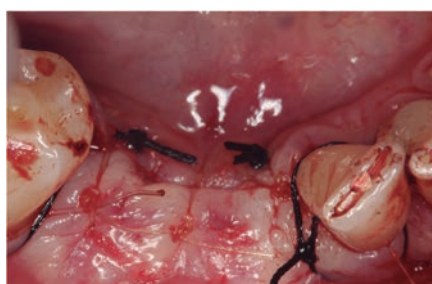The other expander is removed and another osteosynthesis screw is placed in order to prevent the plates from collapsing. It is possible to observe the transversal improvement.



The defect is filled and a tent-pole regeneration is performed using biomaterials (Apatos heterologous bone).



The graft is protected with Derma membrane, fastened with osteosynthesis screws.



It is sutured with monofilament (simple stitches) and silk (containment stitches).

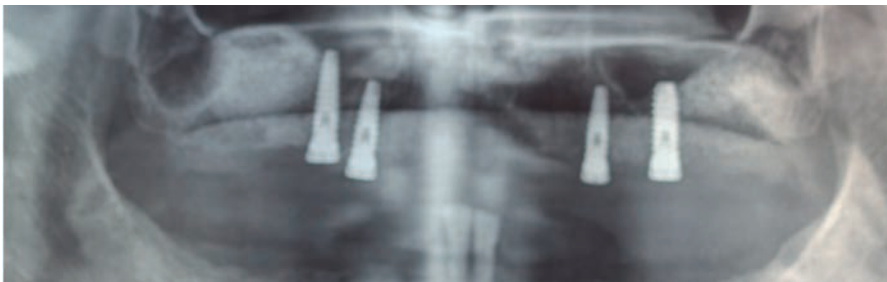
CLINICAL CASE No.3

Clinical photos courtesy of **Dr. Holmes Ortega Mejía**

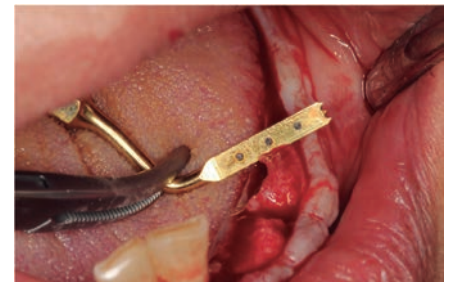Expansion in extreme cases to recover cross-sectional dimension (Complicated Case)

36 year old patient who had his 3rd quadrant teeth extracted approximately 16 years ago. A 2 mm ridge with irregular bone tissue is observed.

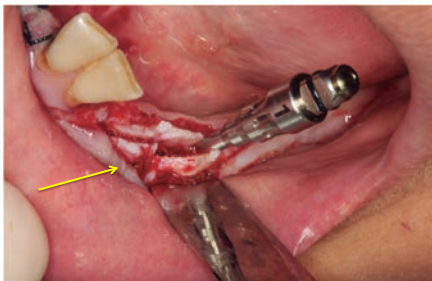
It was decided to make a hybrid prosthesis with 6 implants by first performing an expansion with placement of implants in the same surgical act, in the two hemiarches.



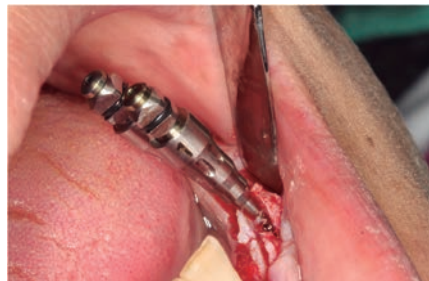X-ray where we observe a lesion at the level of the left sector with absence of bone continuity at the height of 34, which later will fracture the plate.



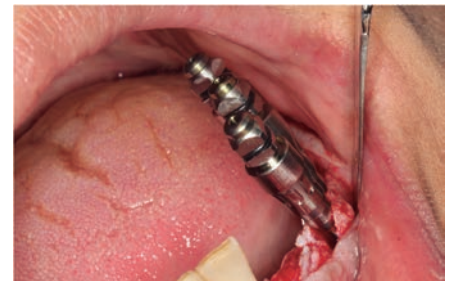The ridge on the left side transversely measures 2 mm.



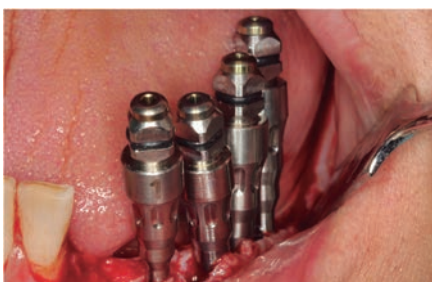Longitudinal corticotomy is performed and the vertical fracture is observed at the level of 34. The yellow expander is placed in the centre of the corticotomy.



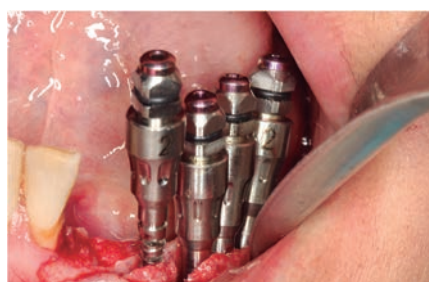The second yellow expander is placed next to the first one, as close as possible but in such a way that it is possible to work comfortably.



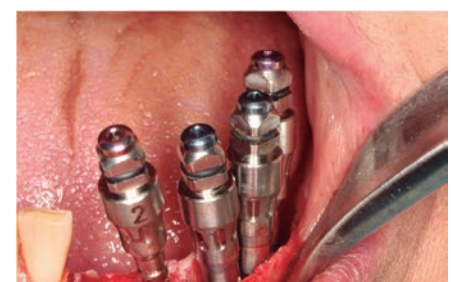By placing a third yellow expander the fracture begins to magnify.



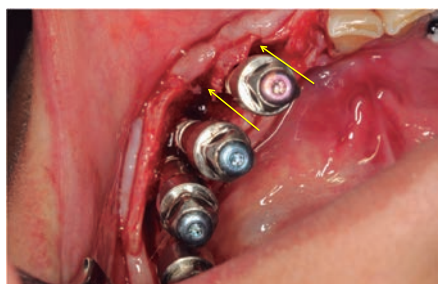
A fourth yellow expander is placed mesial to the fracture.



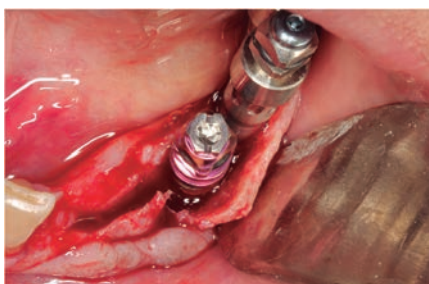The next set of red expanders is placed in the same sequence as the yellow ones, first in the centre and then towards the ends.



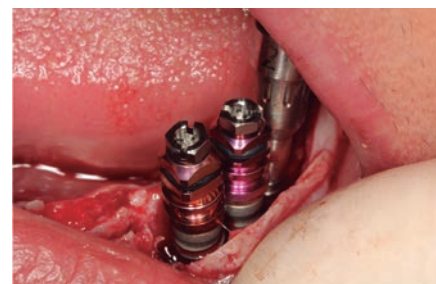The expansion protocol is followed with the blue expanders maintaining the same sequence as the previous ones.



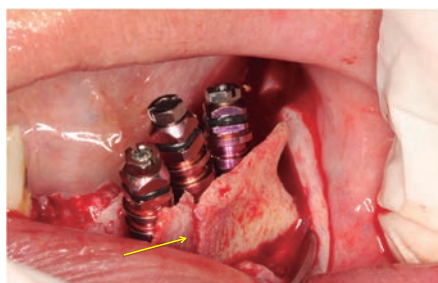
A significant gap in regeneration and double fractures can be observed due to the irregularisation of the remaining bone.



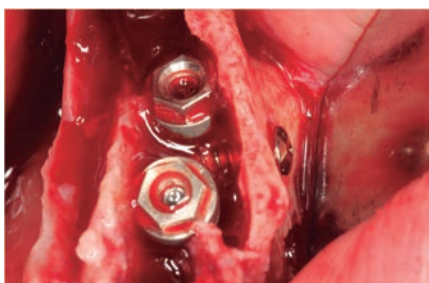
The displacement of the vestibular plate is observed.



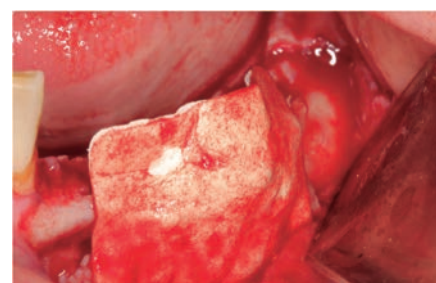
The implants continue to be placed making a buttress of the vestibular plate.



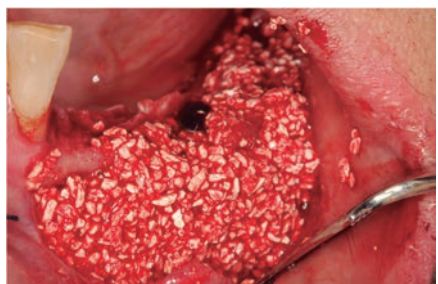A third implant is placed and the fracture of the plate is observed and how the same implant has placed the plate at the same level.



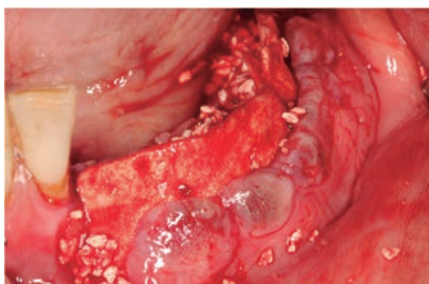Placing the implants 1 mm submerged, an osteosynthesis screw is inserted to stabilise the vestibular plate while maintaining the gap to facilitate regeneration.



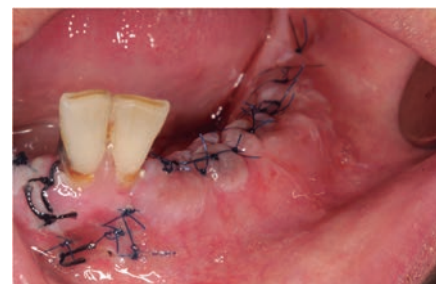A collagen membrane is attached to the bottom of the vestibule.



Subsequently, biomaterials (Apatos heterologous bone) are placed hydrated in their own blood.



The periosteum is cut to allow the tissue to be displaced and sutured.



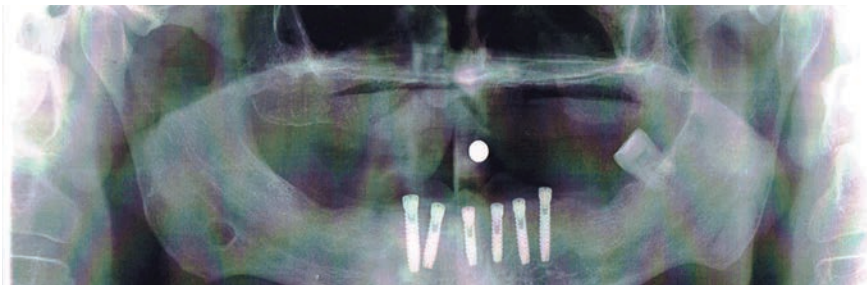
8 days after surgery.

CLINICAL CASE No.4

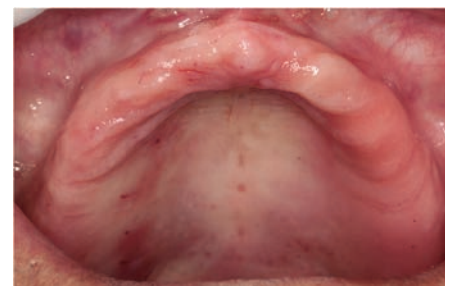Clinical photos courtesy of **Dr. Holmes Ortega Mejía**

Extreme expansion in second attempt at implant placement

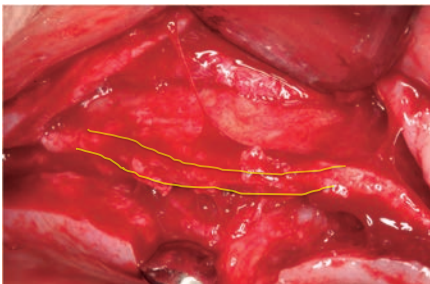
55 year old patient who had his teeth extracted 25 years ago and is wearing a misfit total prosthesis. The patient will have a hybrid placed with 6 implants. Due to the thickness and height of the bone, it was decided to make an expansion and place the implants in a second session.



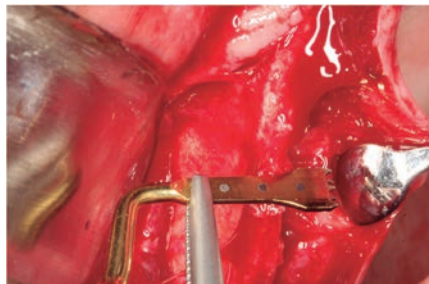
Orthopantomography shows a bone remnant to the sinus with a height of 12 mm. It is decided to ask the patient for a CAT scan before operating, but he does not want to do it, signs the consent forms and decides to have the operation.



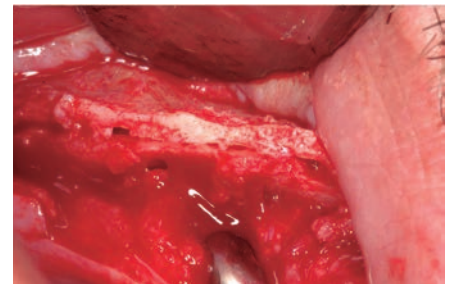
Good keratinised tissue is observed, which facilitates surgery.



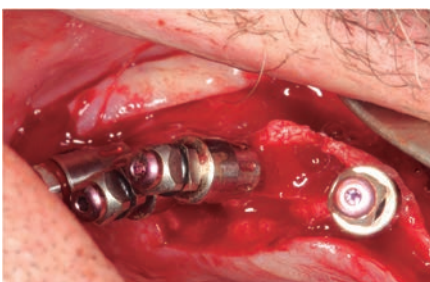Ridge.



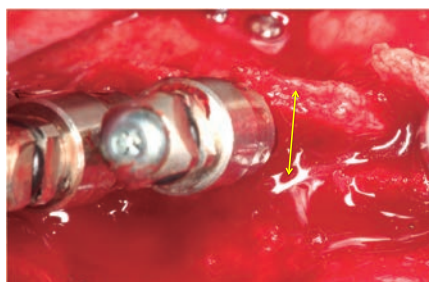
1 mm thick ridge with a height of less than 12 mm.



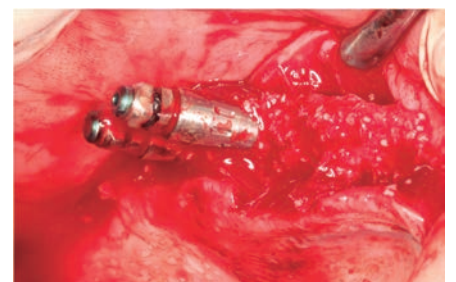
A corticotomy is performed as long and deep as possible.



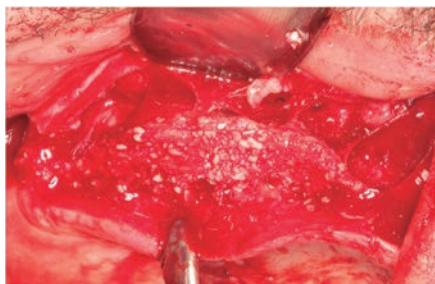
The yellow expanders are placed first and the protocol continues with the red expanders.



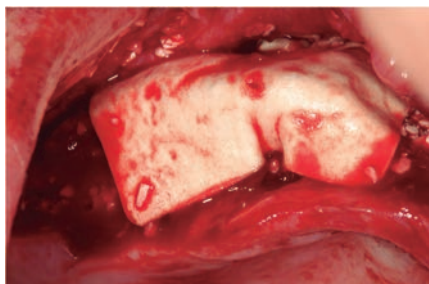
This is followed by the blue expanders and it is possible to see how the expansion begins to show.



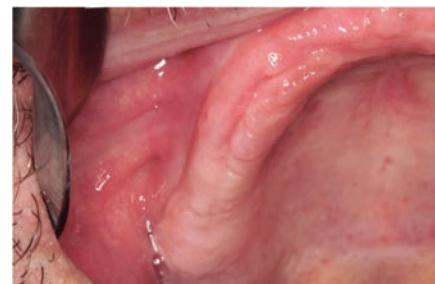The expanders are removed and filled with biomaterials (Apatos heterologous bone).



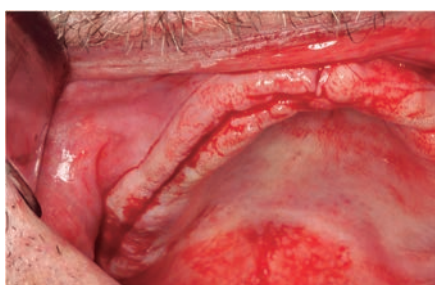The corticotomy of the bone is completely filled in, gaining more than 5 mm in thickness.



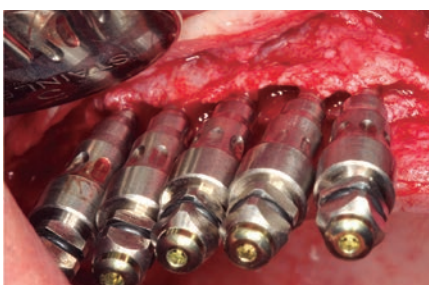
A collagen membrane is attached and sutured.



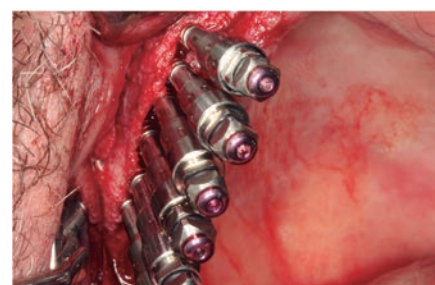
4 months later a second surgery is performed.



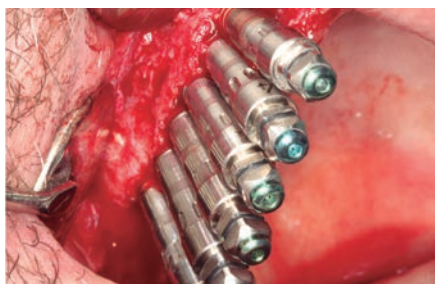
A crestal incision is made.



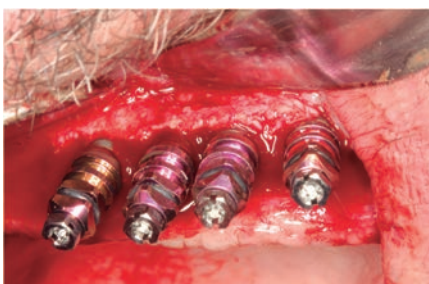
By looking at this image we can be sure that in the expansion performed we only gained 3 mm of the 5 mm we had because we did not use osteosynthesis screws to keep the plates open.



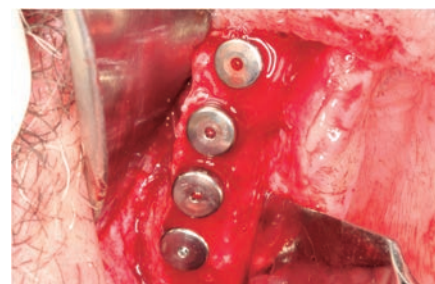
Expansion is continued using the red expanders; in this case 6 sets are used for a more stable expansion.



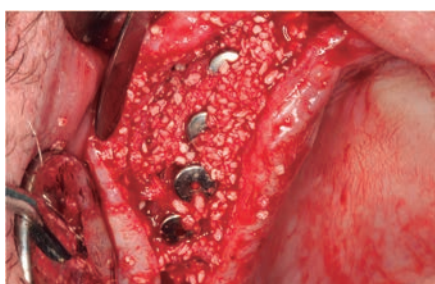6 green expanders.



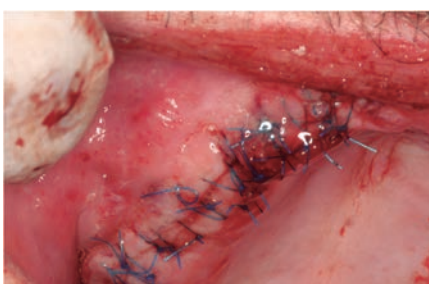Placement of 4 MV 4.20x12 mm expansion implants. The number of expanders is not related to the number of implants.



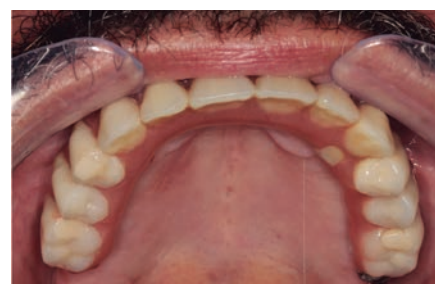Thanks to the previous expansion we can place the implants with good plates that help us to avoid crestal resorption and a less corticalised bone can be observed..



Regeneration occurs with bone and membrane to increase transverse volume.



3 days later good healing can be observed.



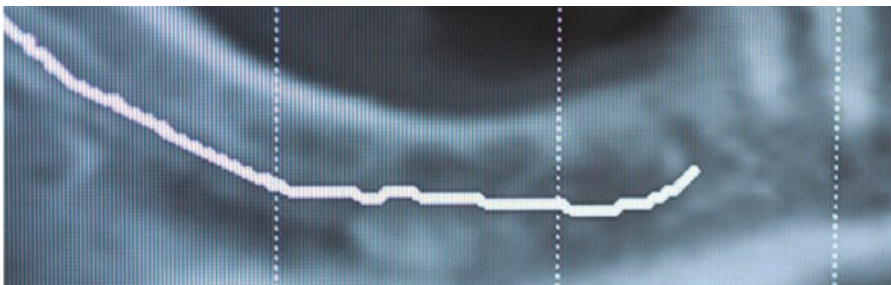
Hybrid prosthesis.

CLINICAL CASE No.5

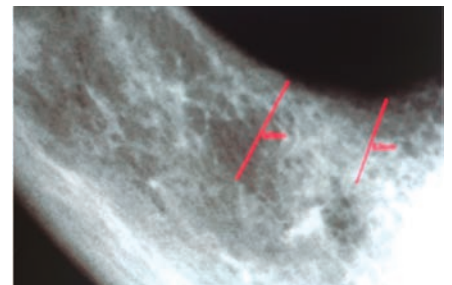
Clinical photos courtesy of **Dr. Holmes Ortega Mejía**

Extreme expansion lateral to the inferior dental nerve

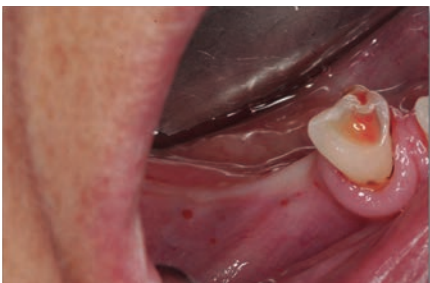47 year old patient who wishes to 'recover the teeth in the lower left sector', it is proposed that teeth 4.4 - 4.5 - 4.6 be restored, placing two implants. The implants are expanded and placed behind the mentonian region and in front of the dental region.



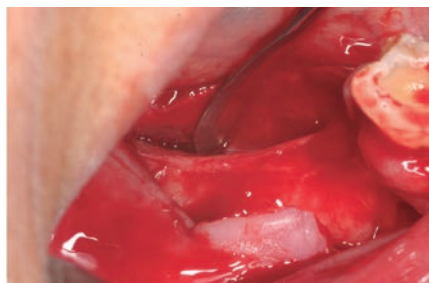
CAT scans show an atrophic bone 5 mm high with a thickness of 3 mm.



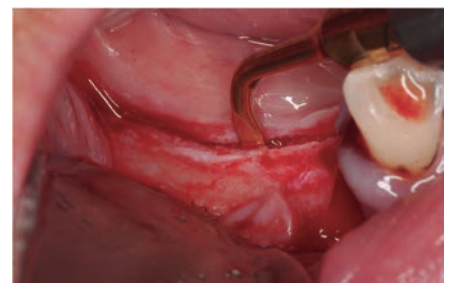Distance to the dental region 5 mm and to the mentonian region 4 mm.



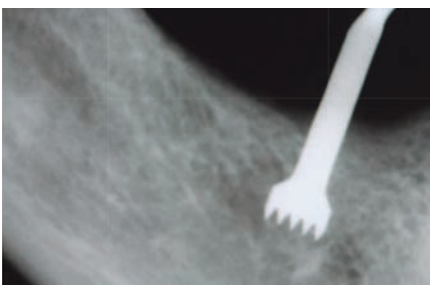
Using supracrestal and supraperiosteal anesthesia and placing only a plunger to keep the area awake, we begin to perform the corticotomy.



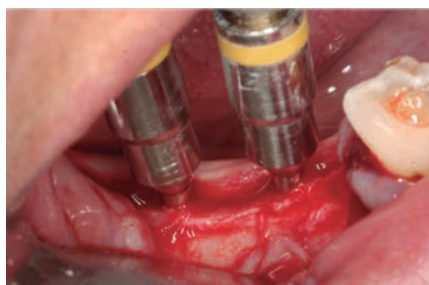The crestal-lingual incision is made.



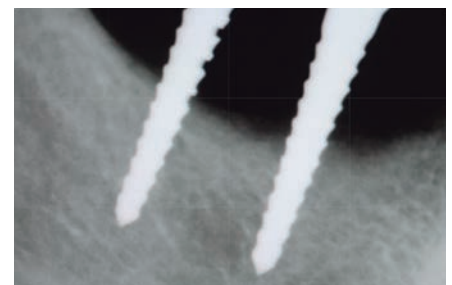
Corticotomy is performed with piezoelectric surgery.



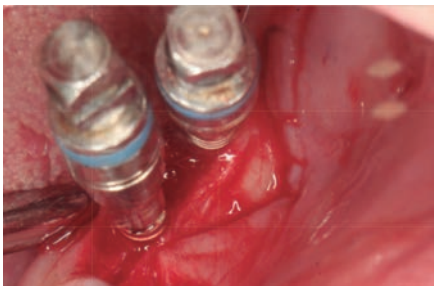
Control X-ray; it is possible to see how we start to pass behind the mentonian region.



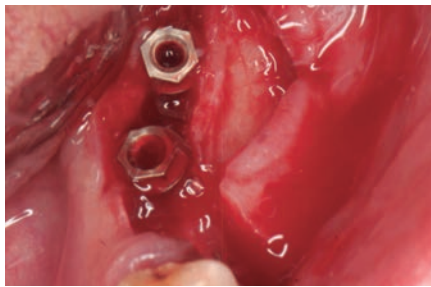
As the corticotomy is short we decide to work with only two sets of expanders.



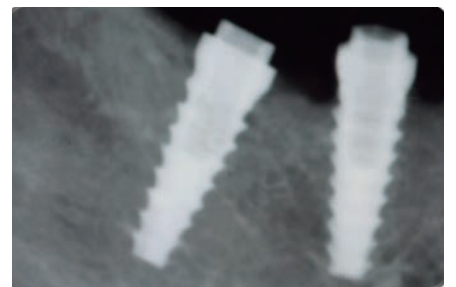
Control X-ray, with red expanders it is possible to see how we are passing behind the teeth.



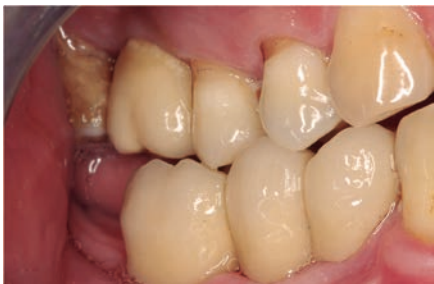Blue expanders at 13 mm depth.



Placement of the MV 4.20x12 mm expansion implants.



X-ray control; the implant can be seen passing behind the dental region and behind the mentonian region.



Final aesthetic.

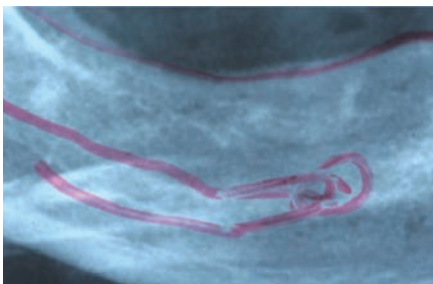
CLINICAL CASE No.6

Clinical photos courtesy of **Dr. Holmes Ortega Mejía**

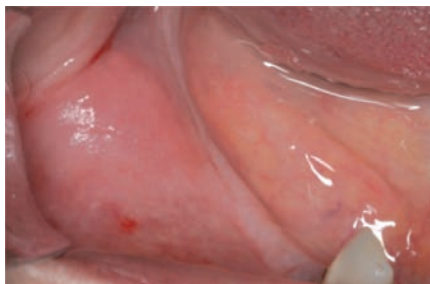Expansion and placement of implants lateral to the nerve

42 year old patient who lost their teeth more than 25 years ago.

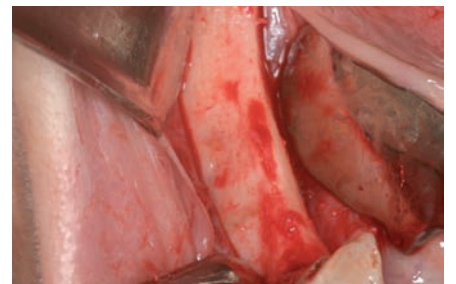
It has a narrow ridge, type C bone, the distance from the ridge to the inferior dental nerve is less than 10 mm. Placement of MV3.80 x12 mm expansion implants in 44 - 45 - 46 using the ESBIPRO Technique.



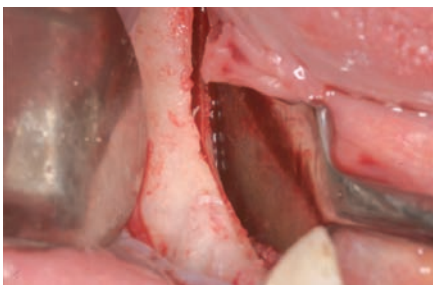Inferior dental nerve and mental nerve loop.



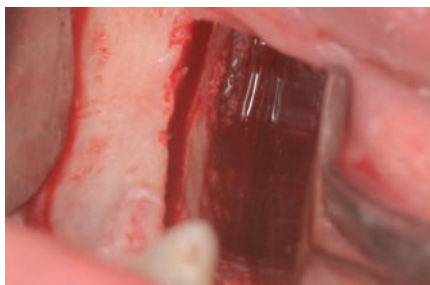Narrow alveolar ridge.




Narrow alveolar ridge type C.



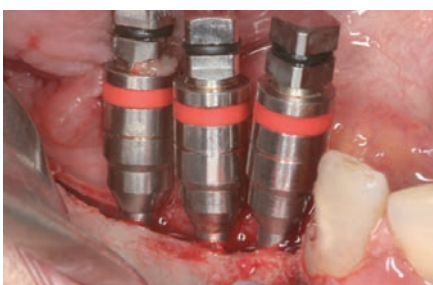Long and lingual ridge corticotomy.




Piezoelectric corticotomy.



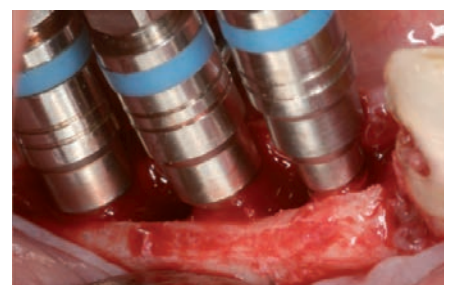
We start the expansion with the yellow expanders.



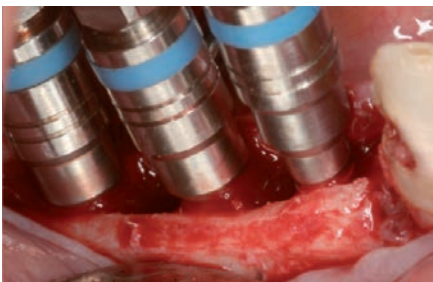
We follow the sequence of expanders.



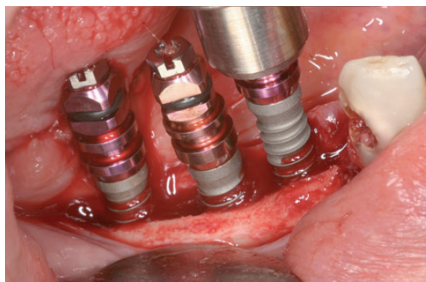
The expansion is progressive.



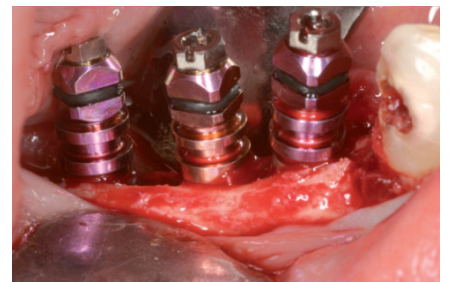
We expand only up to the blue expander to place the 3.80 mm implants.



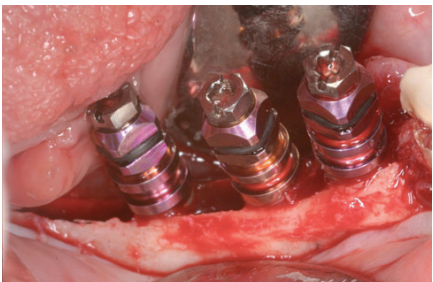
MV implants act as expanders, so always start in the centre.



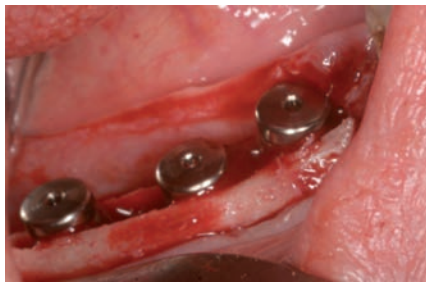
Progressive insertion of the implants.



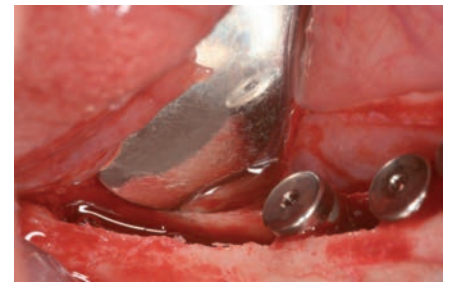
Placement of the MV implants.



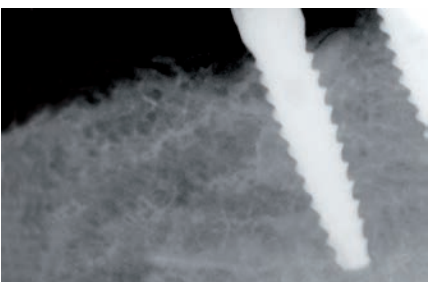
Bone crest expansion.



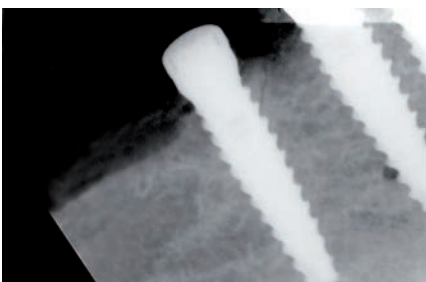
The three implants and their cover screw are placed.



The large dilatation achieved can be observed.



The implants were placed lateral to the nerve.



The patient had no paresthesia of any kind.

CUSTOMER SERVICE

Tel. 93 844 76 50

Hours: Monday to Thursday from 9am to 6pm

Friday from 9am to 3pm

PLACING ORDERS

Tel. 93 844 76 50

E-mail implant@microdentsystem.com

www.microdentsystem.com

Sales representative for your area.

DELIVERY TIMES

Delivery Mainland Spain before 7pm the next day for orders placed before 2pm (Iberian Peninsula).

Delivery between 24-48h for orders placed before 2pm (Canary Islands).

Consult same day delivery options (available only in Barcelona province).

DISPATCH OF PRODUCTS

Always for orders placed before 2pm.

Tell us your chosen time when placing your order:

- 8.30 am Service.
- Preferential: delivery from 8.30am to 10am
- Express: delivery from 10am to 1pm.
- 7pm service: delivery before 7pm. (Default times).

*Available for the whole of mainland Spain. Consult for the Canary Islands.

RETURNS

Returns will not be accepted after a period of 30 days from the delivery of the goods.

All material returns must be accompanied by the product return form duly completed and enclosing a copy of the delivery note.

INVOICING AND METHOD OF PAYMENT

Bank transfer within 30 days of the invoice date.

Consult other payment methods and facilities with our customer service department or the sales representative for your area.

* Microdent reserves the right to make any changes without prior notice.

Important:

- The use of attachments not supplied by Microdent can compromise the stability and fixation of the prosthesis as well as cause loosening or fracture. It also renders the warranty for our implants null and void.

- Consult availability of references according to country as there may be products not marketed in your area.

